

## SUPPORT AND MOVEMENT IN PLANTS AND ANIMALS

1. (a) K - Facet for articulation, with the next vertebra  
L - Transverse process for attachment of muscles
- (b) Cervical or neck region
2.
  - Skeletal muscles have actin and myosin which facilitate contraction and relaxation.
  - High density of mitochondria to provide energy for contraction.
  - Elongated fibres to allow change in length
3. (i) Ball and socket joint
- (ii) Biceps (flexor muscles) relax triceps (extensor muscles) contract.

1.

	Biceps	Gut muscles
(i)	Striated	Un- striated
(ii)	Multinucleated	Un- nucleated
(iii)	Long fibre cylindrical	Short fibred Spindle shaped

2. (a) Femur
- (b) Ball and socket joint
3.
  - a. Attachment of powerful back muscles
  - b. Maintain posture

c. Maintain flexibility of vertebral column

4. (a)

a. Hydrostatic

b. Exoskeleton

c. Endoskeleton

(b) Cervical vertebrae

- Presence of vertebral canal for passage of vertebral artery. Atlas has (broad) surfaces, for articulation with condyles of skull to permit nodding
- Axis has odontoid process/ projection Centrum to permit rotary/ turning. Act as a pivot for atlas.
- Branched/ forked/ short and broad transverse processes for attachment of neck muscles
- Presence of zygapophysis for articulation between vertebrae
- Has short reduced neural spine for attachment of neck muscles. Has wide neural canal for passage of spinal cord and protect it.

**Lumbar**

- Broad / long neural spine for attachment of powerful back muscles.
- Large and well developed transverse processes for attachment of muscles
- Has metamorphosis and hypophysis for muscle attachment. Large thick centrum for support.

- Prezygopophys and post zygotophys present for articulation between vertebrae

**Sacral vertebrae**

- Interior has well developed transverse processes which are fused to the pelvic girdle.
- Vertebrae fused for strength transmit weight of the stationary animal to the rest of the body
- Sacrum has a broad base/ short neural spine for attachment of back muscles

5.

- (a) Ulna
- (b) Radius
- (c) Humerus

6.

- (a) Inter- vertebral discs/ Fibro cartilage
- (b) Absorb shock and reduce friction between the bones

7. Side walls have deposition of lignin to strengthen them

8.

- (a) Y- Femur  
Y- Tibia  
Z- Fibula
- (b) (i) Synovial fluid

- (ii) Absorb shock/ reduce friction between joints
- (c) Ligament
- (d) Ball and socket – allow movement in all direction  
Hinge joint- Allow movement in one plane only
- (e) Sigmoid notch

9.

- (a) Have short neural spines
- (b) - Xylem tissues  
- Collenchymas tissues  
- Sclerenchyma tissues  
- Parenchyma tissues

10. (a)

Type of muscle	Where found
(i) Skeletal	Attached bones and skeleton
(ii) Smooth	Walls of tubular structures
(iii) Cardiac	Heart muscles

- (b) Ball and socket joint – allows movement in all directions i.e  $360^{\circ}$   
Hinge joint- Allows movement only on one plane i.e  $180^{\circ}$
- (c) It is a slippery fluid that lubricates the joints reducing friction during movement.

- (d) - Prevents drying out of organism
- Controls size of the organism
- Provides protection against microbial infections and mechanical injury.

11.

- a. Support and protects inner delicate tissues
- b. Prevents excessive loss of water from body tissues
- c. Provides surfaces for muscle attachment.

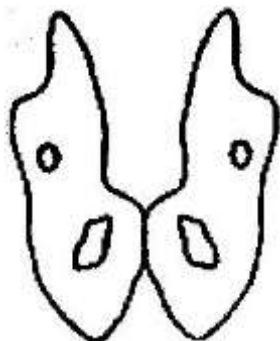
12.

- (a) Dorsal fin – Prevented rolling or yawing
- (b) Pectoral and pelvic fins- used for steering and prevent pitching
- (c) Caudal fin – steering and forward propulsion

13.

- a. Contract spontaneously and do not fatigue.
- b. Innervated by the autonomic nervous system
- c. Contractions are initiated from within the muscles
- d. Thy are myogenic

14. (a)



c) Femur – Articulates with acetabulum

Sacrum – articulates with ilium

15. Tendons – Tissues between muscles and bone in a joint

Ligaments – Tissues between bone and another bone in a joint

16. They are muscles that contract while the others relax e.g triceps and biceps muscles.

17. (a)

- Xylem vessels
- Collenchyma
- Sclerenchyma

(b) Xylem- lignified on the side walls

Collenchyma – thickened by deposition of cellulose and pectic compounds

Sclerenchyma – lignified on the cell walls.

18. (a)
- Immovable joints
  - Synovial (movable) joints)
  - Gliding/ sliding joints

- (b)
- Immovable joint – Cranium / skull
  - Synovial joint – between limbs
  - Gliding / sliding joint- vertebral column

- 19.
- Turgidity of the parenchyma cells
  - Presence of collenchyma tissues

## 20. **Skeletal muscle**

- a. Attached to the skeleton
- b. They are striated/ fibres that allow contractions
- c. Presence of mitochondria to provide energy for contractions
- d. Have antagonistic contractions to enhance movement

## **Cardiac muscle**

- a. They are the heart muscles
- b. Highly connective tissues to allow harmonious contraction
- c. They do not fatigue
- d. Ends are intercalated to transmit impulses throughout the heart

## **Smooth muscle**

- a. Walls of tubular organs
- b. Capable contracting slowly
- c. Innervated by autonomic nervous
- d. System/ involuntary movement